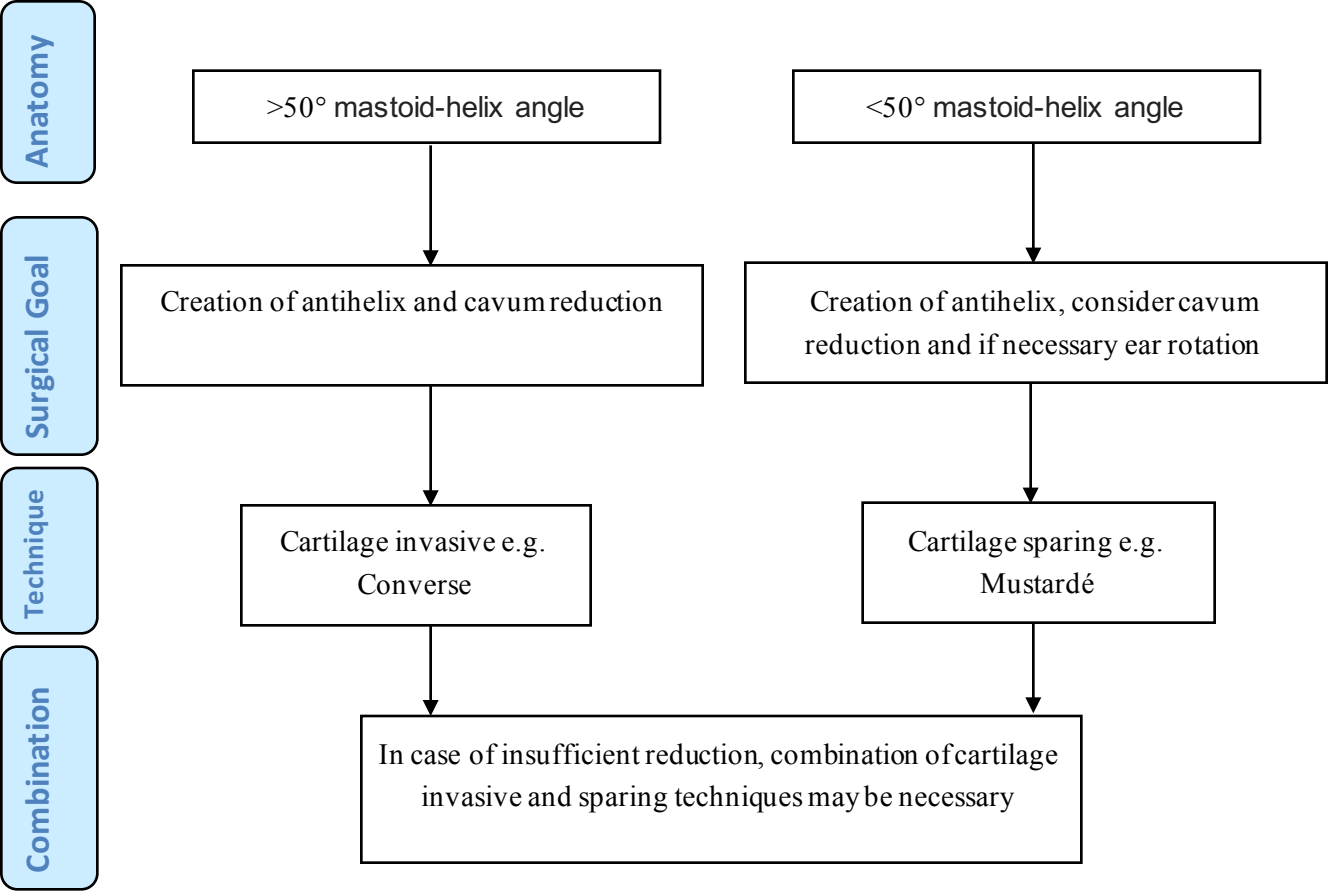
Anatomy
Surgical Goal
Technique
Combination
>50° mastoid-helix angle
<50° mastoid-helix angle
Creation of antihelix and cavum reduction
Creation of antihelix, consider cavum reduction and if necessary ear rotation
Cartilage invasive e.g. Converse
Cartilage sparing e.g. Mustardé
In case of insufficient reduction, combination of cartilage invasive and sparing techniques may be necessary